

Fassier-Duval

Telescopic IM System™

SURGICAL TECHNIQUE



TABLE OF CONTENTS

The Fassier-Duval Telescopic Intra-Medullary System™ is an innovative nail designed for patients suffering from Osteogenesis Imperfecta (OI), skeletal dysplasia and other bone deformities. It was created to prevent or stabilize fractures, or correct deformity of the long bones whilst growth occurs. It is indicated for children 18 months and older suffering from OI, pseudoarthrosis and can also be used concomitantly with external fixators in older children or short statured adults with limb length discrepancy. The Fassier-Duval Rod has been designed for the femur, tibia and humerus.

The FD Rods are manufactured in medical grade Stainless Steel (SS316L, ASTM F138) and are available in five diameters: 3.2, 4.0, 4.8, 5.6 and 6.4 mm.

Femoral Nail

Choice of Technique	4
Choice of Nail Size	4
Open Osteotomy Technique	5
Percutaneous Technique	10
Femoral Implant Specifications	11

Tibial Nail

Choice of Nail Size	12
Open Osteotomy Technique	13
Additional Fixation Options	17
Tibial & Humeral Implant Specifications	19

Humeral Nail

Background	20
Open Osteotomy Technique	22
Closure	23

Developed in collaboration with:

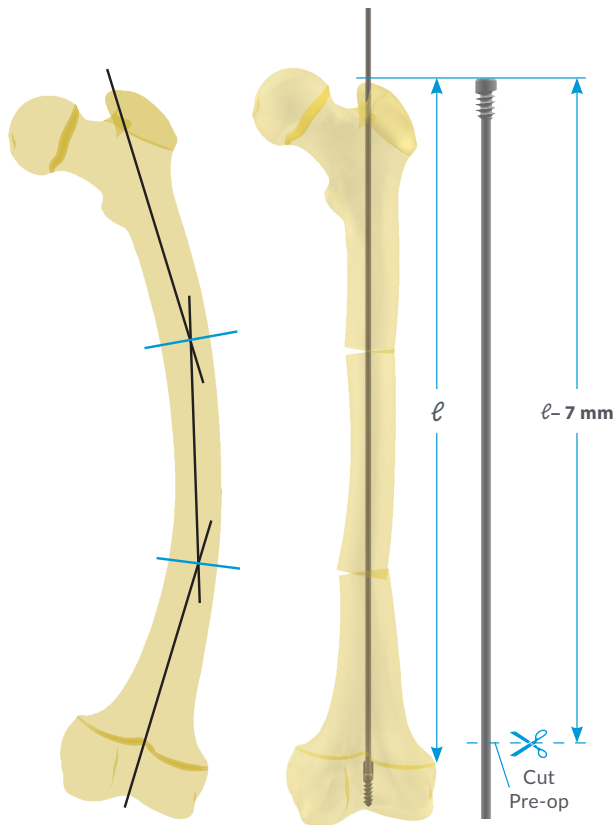
François Fassier, MD, FRCS(C)
Shriners Hospital for Children
Montreal, Quebec, Canada

Pierre Duval, MD, FRCS(C)
Hôpital Brôme-Missisquoi-Perkins
Montreal, Quebec, Canada

Dror Paley, MD, FRCS(C)
St Mary's Hospital
West Palm Beach, Florida, USA





SURGICAL TECHNIQUE

Femur | Pre-OP Planning



Cut the Female Component to a length of $\ell - 7$ mm. The Male Component is cut intra-operatively after both components are implanted.

The choice of L (long thread), S (short thread) or LON series (pin fixation), which defines the length of the distal thread or non-threaded fixation, is based on the height of the distal epiphysis as measured from A-P x-ray film.

Femur Type	Femoral Nail Distal Fixation Options		
			
Size	Long Thread (L)	Short Thread (S)	Pin Fixation (LON)*
3.2	10 mm	5 mm	1.6 mm
4.0	11 mm	6 mm	1.8 mm
4.8	12 mm	7 mm	2.0 mm
5.6	13.5 mm	8.5 mm	2.4 mm
6.4	15 mm	10 mm	2.8 mm

* Dimensions define the size of the wire or Peg used for interlocking. See p.15 for more details.

Choice of the Technique

The standard technique employed is the open osteotomy technique. However, for patients with large bones and thin cortices, the use of the percutaneous technique is recommended.

Choice of Nail Size

Diameter Consideration

Selection of the Nail diameter is based on the size of the isthmus of the medullary canal.

Length Considerations

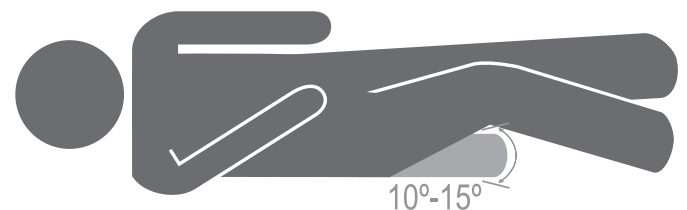
Estimate the distance (ℓ) between the greater trochanter and the distal growth plate of the rectified bone after osteotomy (ies). The maximum length of the uncut Nail should be long enough to reach the distal epiphysis.

Patient Positioning

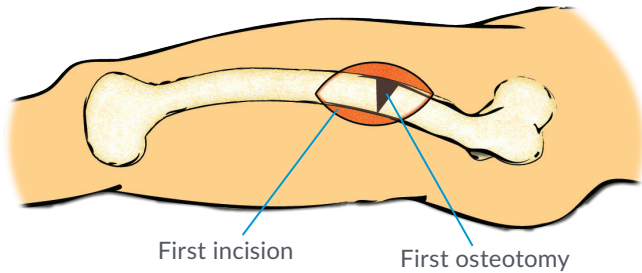
Place the patient on the edge of a radiolucent OR table in a modified supine position, with the affected limb elevated using a folded sheet or saline bag and the ipsilateral arm secured across the torso.

Position the C-arm to allow visualization of the proximal femur in both A-P and sagittal views.

The affected leg can be adducted $10-15^\circ$ and the torso bent away from the affected leg to facilitate access to the tip of the greater trochanter.



Femur | Open Osteotomy technique



Step 1: Incision

Through a classic postero-lateral approach, expose the femur subperiosteally. Subsequently, execute the first osteotomy under C-arm guidance.

CAUTION: Oscillating saw should be avoided when performing osteotomies to prevent osteonecrosis and delayed healing.

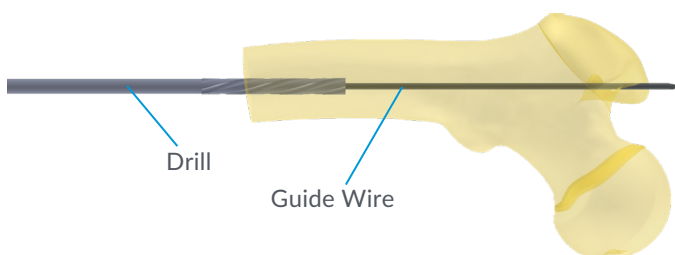
Step 2: Reaming

The diameter of the Drills provided with the instrument set are approximately 0.3 mm larger than the diameter of the correspondent Fassier-Duval Nail.

Ream the proximal fragment retrograde over a Guide Wire with the cannulated Drill up to and through the greater trochanter. Prepare the distal fragment in the same fashion aiming in the middle of the canal.

If the Guide Wire does not reach the distal epiphysis, a second osteotomy should be performed after reaming the intermediate fragment.

CAUTION: Do not ream the distal growth plate and distal epiphysis; this will result in loss of fixation of the Male Component.

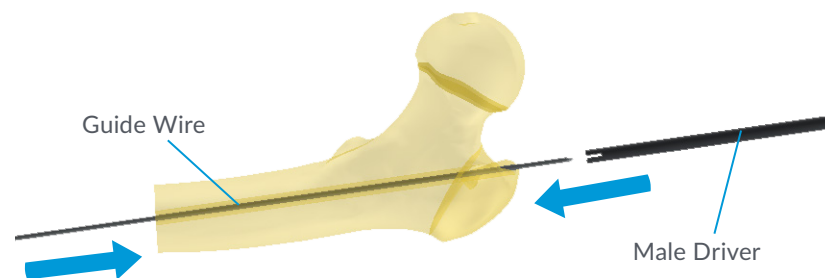


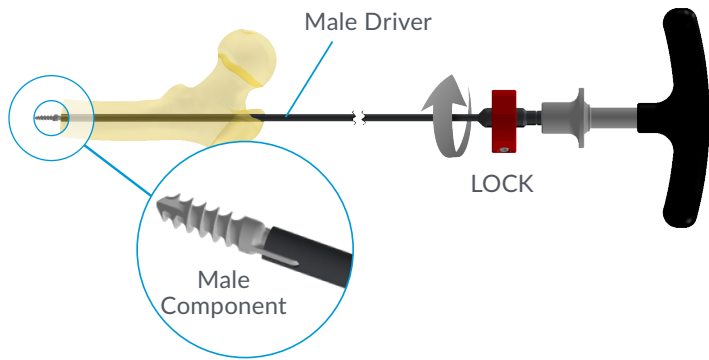
Nail	Reamer	G-Wire	
Size	Cat #	Size (mm)	Cat #
3.2	DR132 DR132L	Ø 1.6 L=450	G-WIRE 016
4.0	DR140 DR140L	Ø1.6 / Ø1.8 L=450	G-WIRE016 / G-WIRE018
4.8	DR148	Ø 2.0 L=450	G-WIRE 020
5.6	DR156		
6.4	DR164		

Step 3: Male Driver

Insert a 2.0 mm Guide Wire retrograde from the most distal osteotomy up through the greater trochanter. Make a second incision at the buttock to allow the Guide Wire to exit proximally. Slide the Male Driver corresponding to the Nail size over the Guide Wire up to the osteotomy.

Nail	Male Driver	
Size	Cat #	Color
3.2	MDr132-L	Yellow
4.0	MDr140-L	Red
4.8	MDr148-L	Blue
5.6	MDr156-L	Black
6.4	MDr164-L	Rust

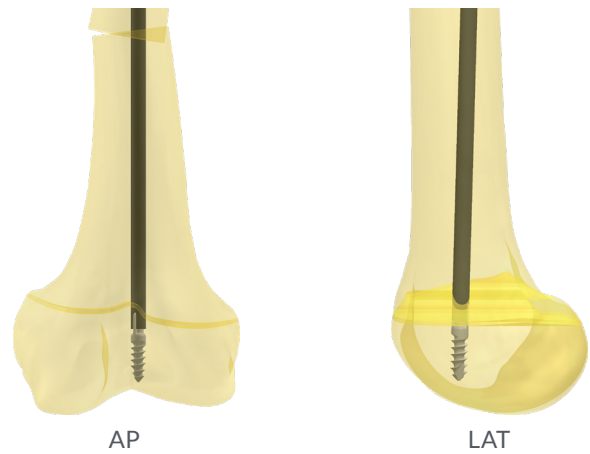
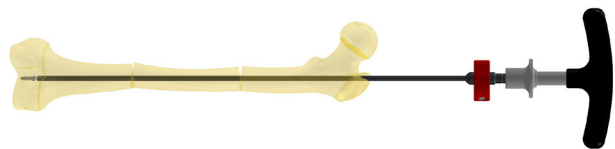




Step 4: Male Component Assembly

Remove the Guide Wire from the Male Driver, and insert the Male Component; ensure that the wings of the Male Component are properly engaged into the Male Driver's slots.

The Male Drivers can be locked onto the Male Component to facilitate manoeuvring of the Nail upon insertion. To lock with the Male Component after it is inserted inside the Male Driver, rotate the plastic ring to the LOCK position with reference to the line on the metal shaft of the Male Driver.



Step 5: Male Component Insertion

Advance the Male Component distally after reduction of the osteotomy (ies) and screw into the distal epiphysis.

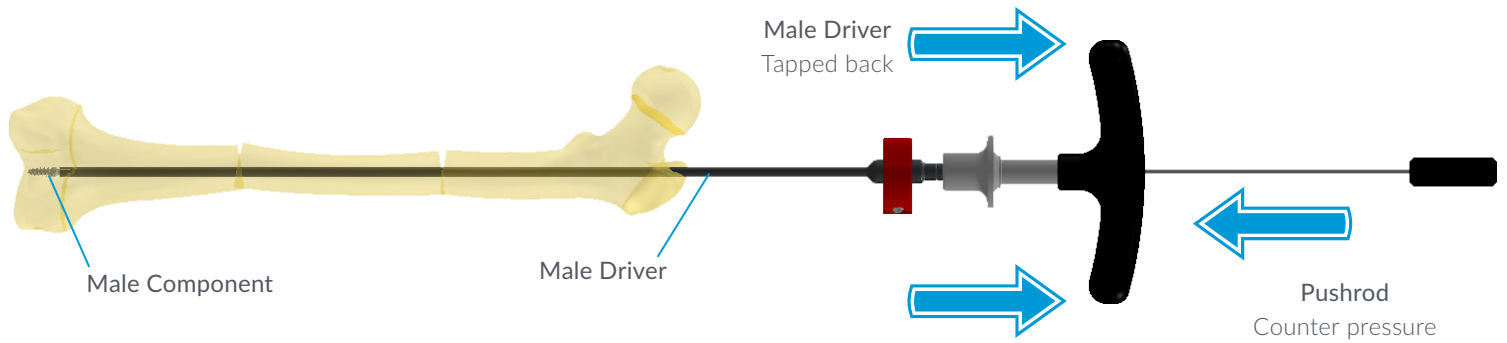
Verify under fluoroscope that the distal thread is positioned beyond the growth plate, otherwise normal growth may be affected. Optimal position of the Male Component on the distal femoral epiphysis is achieved by centering the distal tip on both the antero-posterior and the lateral views.

The use of long threaded fixation (L) is recommended for the femur. However all threads should be beyond the physis and into the epiphysis.

Once the Male Component has been screwed into the distal epiphysis, unlock the Male Driver by rotating the plastic ring to the UNLOCK position before pulling out the Male Driver.

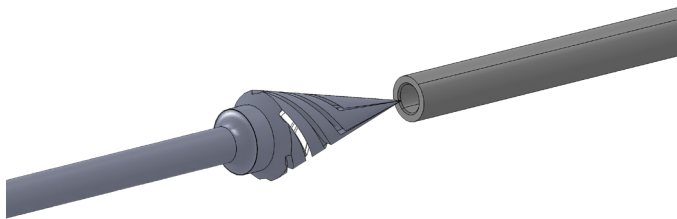
CAUTION: Failure to unlock the Male Driver may result in the Male Component being pulled out of the epiphysis and consequently lack a secure fixation.

CAUTION: The Male Driver is designed only to screw the Male Component; do not use the Male Driver to reduce the fracture. Align the bone segments before advancing the Driver into the canal. Incorrect use of the Male Driver could result in instrument damage.



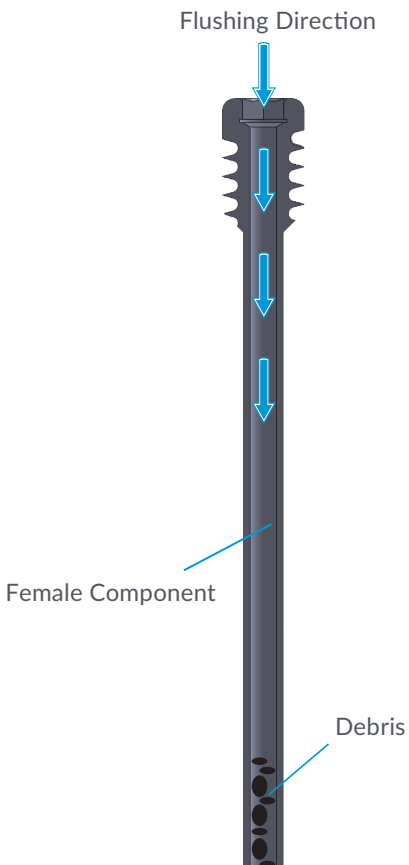
Step 6: Male Driver Removal

Use the Pushrod [PSR100] when pulling out the unlocked Male Driver to reduce stress on the Nail fixation. Gently reverse-tapping the T-Handle with a small mallet can help remove the Male Driver.



CAUTION: The de-burring tool should be operated at low speed or by hand.

Flush the cannula using saline solution or sterile water. Validate free sliding with a Male Component of the same size. If resistance is felt, repeat de-burring process.



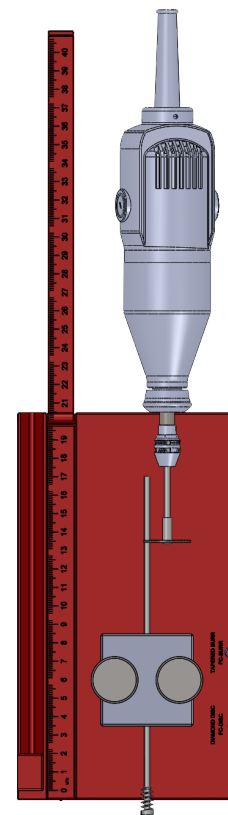
Step 7: Female Component Cutting

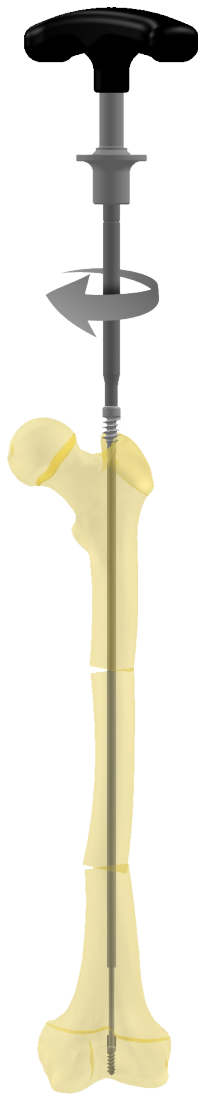Measure and mark the Female Component length under furoscopy by directly laying the implant on the patient's leg. The mark should be proximal to the distal growth plate. Cut the implant on a side table using a high-speed cutting disc [FC-DISC]. Please refer to Female Cutting brochure for more detailed information.

CAUTION: Do not cut the Female Component with a standard surgical rod or wire cutter, because it will crimp the end of the Nail and obstruct normal telescoping.

CAUTION: Use saline solution or sterile water to reduce heating and particle generation during cutting.

Female Cutting Jig





The threaded portion of the Female Component must only be inserted in the non-ossified portion of the greater trochanter, and not in the ossified metaphysis. The non-threaded part can be left within the cartilage. Remove the Female Driver when adequate position is achieved.

CAUTION: If the Female Component is fixed to the ossified metaphysis, the greater trochanter will continue to grow above giving the impression that the nail is “sinking in the shaft”.

Step 9: Male Cutter

Assemble the Male Cutter [MC200] using the corresponding inner and outer sleeves. For more detailed instructions please refer to the Male Cutting brochure.

Through a 2.5 cm incision, cut the Male Component.

		Description	Catalog #
Components		Male Cutter Handle	MC200-HANDLE
		Male Cutter Knob	CK200
		Outer Sleeve	MC200-TUBE 32* MC200-TUBE 40 MC200-TUBE 48* MC200-TUBE 56 MC200-TUBE 64
		Inner Sleeve	


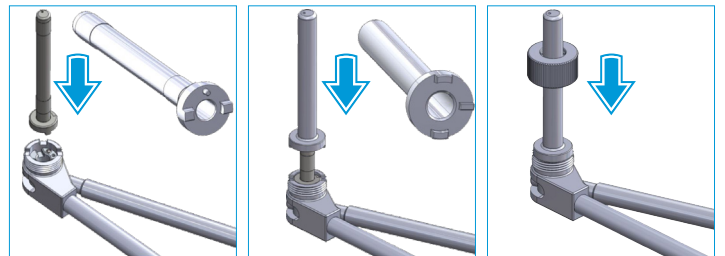
Optional tubes from the previous generation: 3.2 mm implants can be cut using MC200-TUBE 40, and 4.8 mm implants can be cut using MC200-TUBE 56.

Step 8: Female Component Insertion

Slide the Female Component over the Male Component and screw it into the greater trochanter using the appropriate Female Driver.

CAUTION: The Female Driver should be kept aligned with the Female Nail during insertion. Lateral forces (bending) may cause the failure of the hexagonal tip of the Female Driver.

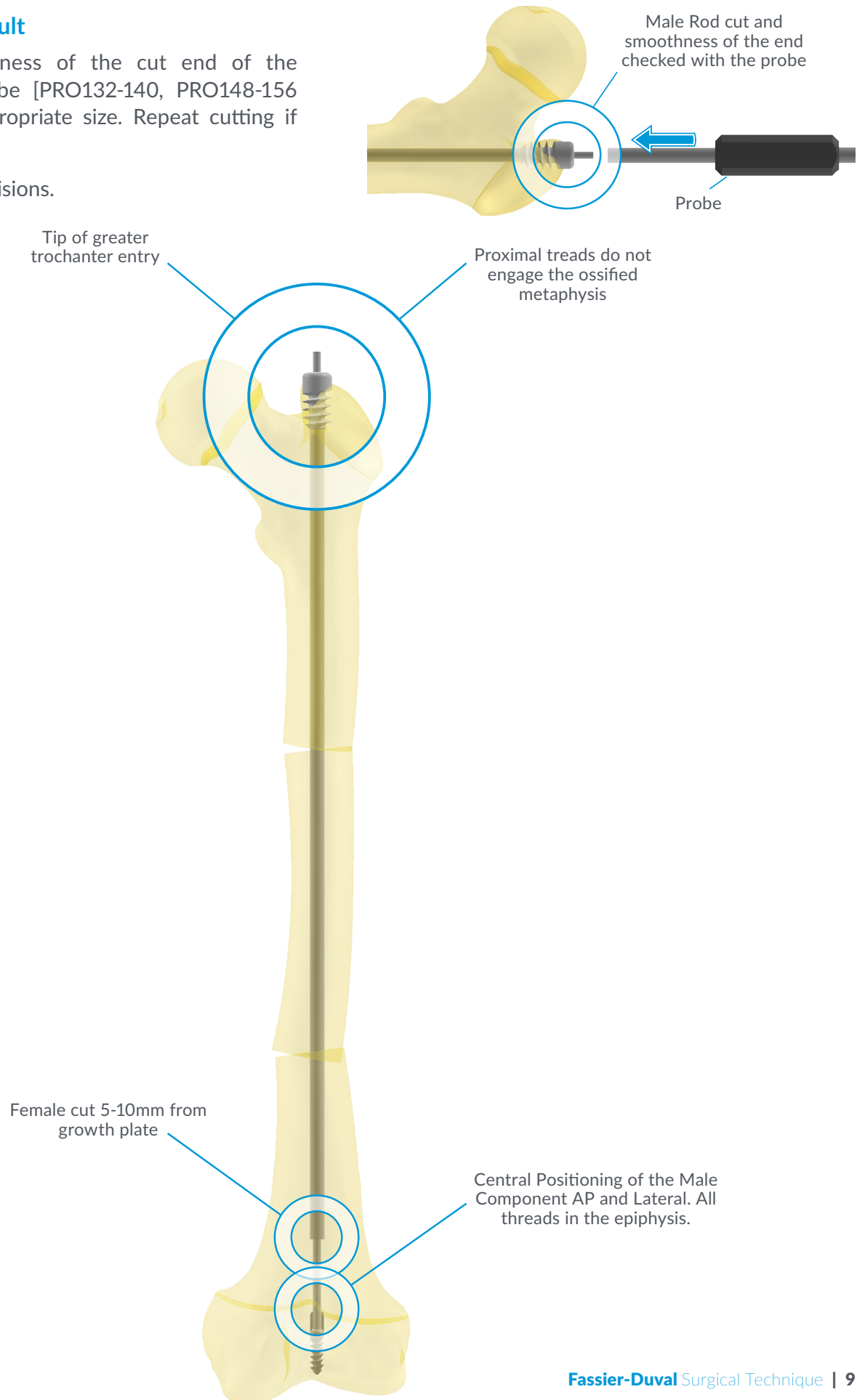
Nail	Female Driver	
Size	Cat #	Hex Size
3.2	FDR100	4.0 mm
4.0	FDR102	5.0 mm
4.8		
5.6	FDR101	
6.4		



Step 10: Final Result

Verify the smoothness of the cut end of the Male with the probe [PRO132-140, PRO148-156 or PRO164] of appropriate size. Repeat cutting if necessary.

Finally, close the incisions.



Femur | Percutaneous technique

Step 1: Percutaneous Reaming

After insertion of the Guide Wire through the greater trochanter to the apex of the deformity, ream the femur to the appropriate size using the provided cannulated Reamers.

Step 2: First Osteotomy

Perform the first osteotomy (through a 0.5 cm incision) in the convexity of the deformity, just distal to the Reamer.

Step 3: Acute Correction

With counterpressure applied at the osteotomy site (with a mallet for example), progressively correct the deformity (osteoclasis) by gentle manipulation.

When the bone is straightened, push the Guide Wire distally and advance the Reamer accordingly.

Step 4: Second Osteotomy


Push the Guide Wire distally to the apex of the second deformity. Then, perform the second osteotomy at the extremity of the Reamer, following the same procedure described in steps 2 and 3 until the whole length of the medullary canal is reamed until just before the growth plate.

Step 5 To 10: To Open Osteotomy

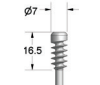

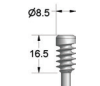



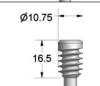

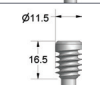

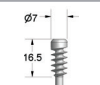

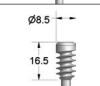

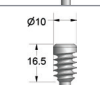

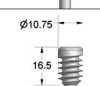

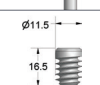

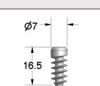

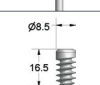

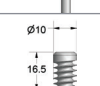

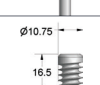

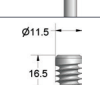

The Male and Female Components can now be inserted.


See the Open Osteotomy Technique (page 5, steps 5 to 10).

CAUTION: Applying traction on the femur will help maintain alignment of the osteotomies when the Reamer is removed and exchanged with the Male Component.

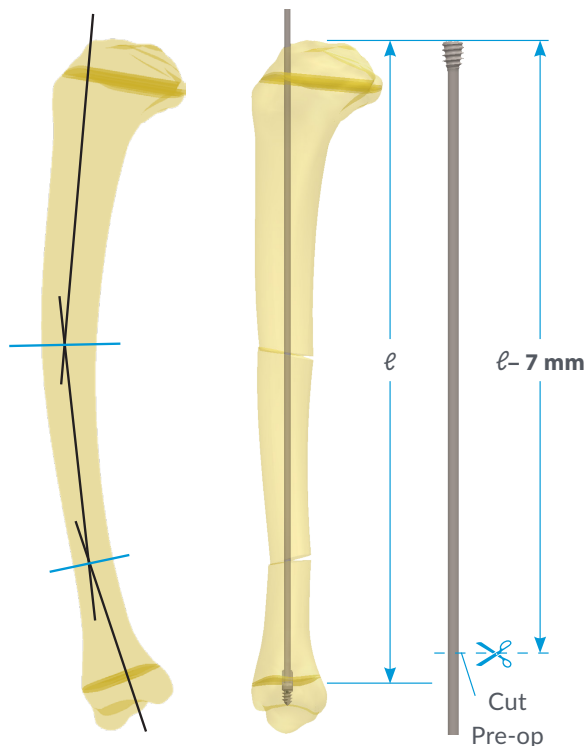


Femur | Implant Specifications

Catalog #	Size X Length	Proximal Fixation	Distal Fixation
Femoral Implants Long Thread			
FD-032(L)-SS	Ø 3.2 X 202 Ø 3.2 X 267		
FD-040(L)-SS	Ø 4.0 X 338		
FD-048(L)-SS	Ø 4.8 X 409		
FD-056(L)-SS	Ø 5.6 X 410		
FD-064(L)-SS	Ø 6.4 X 412		
Femoral Implants Short Thread			
FD-032(S)-SS	Ø 3.2 X 197 Ø 3.2 X 262		
FD-040(S)-SS	Ø 4.0 X 333		
FD-048(S)-SS	Ø 4.8 X 404		
FD-056(S)-SS	Ø 5.6 X 405		
FD-064(S)-SS	Ø 6.4 X 407		
Femoral Implants Pin Locking – LON			
FDLON-F032-SS	Ø 3.2 X 194 Ø 3.2 X 259		
FDLON-F040-SS	Ø 4.0 X 330		
FDLON-F048-SS	Ø 4.8 X 400		
FDLON-F056-SS	Ø 5.6 X 401		
FDLON-F064-SS	Ø 6.4 X 401		



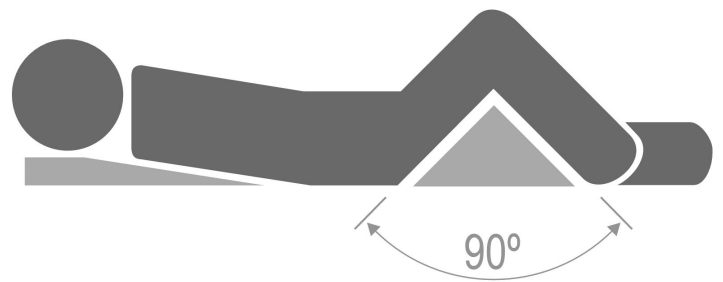
Tibia | Pre-Op Planning



Length Considerations

Estimate the distance (ℓ) between the superior margin of the ossified proximal epiphysis and the distal growth plate of the rectified bone after osteotomy (ies) and x-ray magnification correction if necessary. The maximum length of the uncut Nail of the chosen size should be long enough to reach the distal epiphysis. The length of the female hollow component is cut intra-operatively to a length of $\ell - 7 \text{ mm}$

Check that the height of the proximal tibial epiphysis is more than 12 mm to accommodate the proximal thread. The choice of SPS (short) or LON series, which defines the type of distal fixation, should be based on the height of the distal epiphysis as measured from A-P x-ray film.






Choice of the Technique

The standard technique usually employed is the open osteotomy technique. Percutaneous technique is not recommended for the tibia.

Choice of Nail Size

Diameter Consideration

Selection of the Nail diameter is based on the size of the isthmus of the medullary canal.

Distal Fixation options			
			
Size	Proximal hole*	Short Thread-S	Pin Fixation-LON*
3.2	2.0 mm	5 mm	1.6 mm
4.0	2.0 mm	6 mm	1.8 mm
4.8	2.0 mm	7 mm	2.0 mm
5.6	2.4 mm	8.5 mm	2.4 mm
6.4	2.8 mm	10 mm	2.8 mm

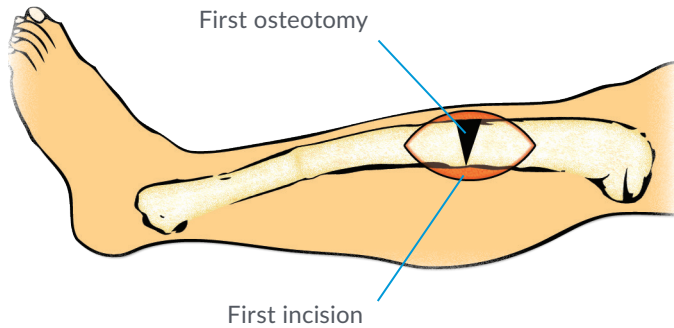
*Dimensions define the size of the wire or Peg used for interlocking.

See p.15 for more details.

Patient Positioning

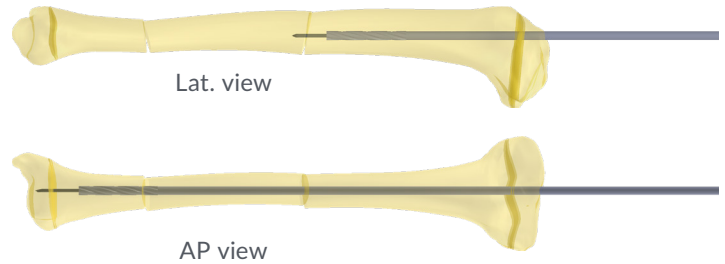
Place the patient in a supine position on the surgical table with the knee of the affected limb flexed at 90°.

Tibia | Open Osteotomy technique



Step 1: Incision

Through a classic anteromedial approach, the patellar tendon is retracted laterally to expose the proximal tibia. The pre-spinal extra-articular surface of the tibial plateau should be exposed. Create an entry portal using a tibial awl or a Guide Wire. The apex of the tibial deformity is exposed through an anterior approach. The periosteum is elevated and after checking the level of the first osteotomy with the C-arm, the osteotomy is done. Once completed, an osteoclasis or osteotomy of the fibula is done.



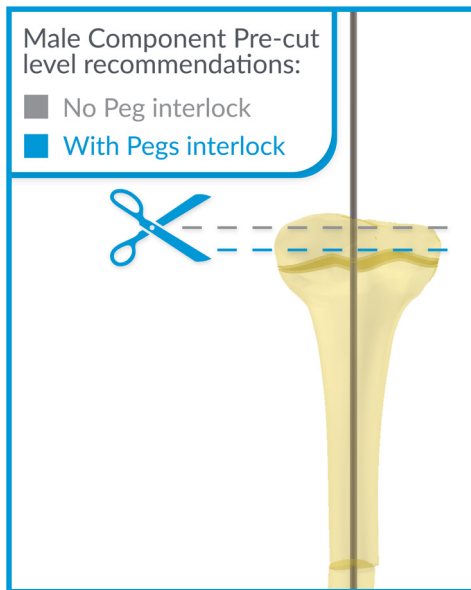
Step 2: Reaming

Insert the Guide Wire anterograde from the tibial plateau with special care not to bend it. Preparation of the proximal fragment is done with a cannulated Reamer (see table). Reaming can also be done retrograde from the osteotomy site. All Reamers provided in the system are 0.3 mm larger than the diameter of the Fassier-Duval Nail size chosen. The distal fragment is prepared in the same fashion. If the Guide Wire does not reach the distal epiphysis, a second (or third) osteotomy should be performed after reaming the intermediate fragment.

Align the fragments over the Reamer to achieve a neutral position of the distal fixation. The Guide Wire axis must be perpendicular to the joint line on the A-P view and in the middle of the epiphysis on the lateral view.

CAUTION: Do not ream the distal growth plate and distal epiphysis; this will result in loss of fixation of the Male Component.

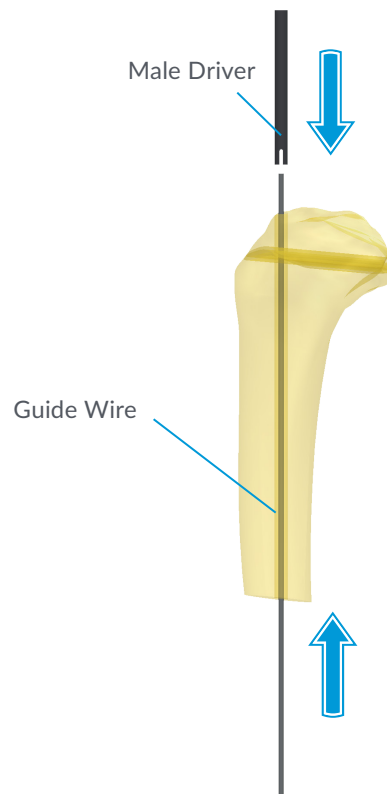
Nail	Reamer	G-Wire	
Size	Cat #	Size (mm)	Cat #
3.2	DR132 DR132L	Ø 1.6 L=450	G-WIRE 016
4.0	DR140 DR140L	Ø1.6 / Ø1.8 L=450	G-WIRE016 / G-WIRE018
4.8	DR148	Ø 2.0 L=450	G-WIRE 020
5.6	DR156		
6.4	DR164		



Step 3: Male Pre-Cut (Optional)

To prevent the protrusion of the Male Component in the joint space, it is recommended to pre-cut the Male Component prior to insertion. The Implant is measured and marked by overlaying it on the patient's leg. The cut should be above the proximal growth plate but below the articular cartilage.

Important: If the Male Component is pre-cut, the ability to lock it onto the Male Driver is lost.



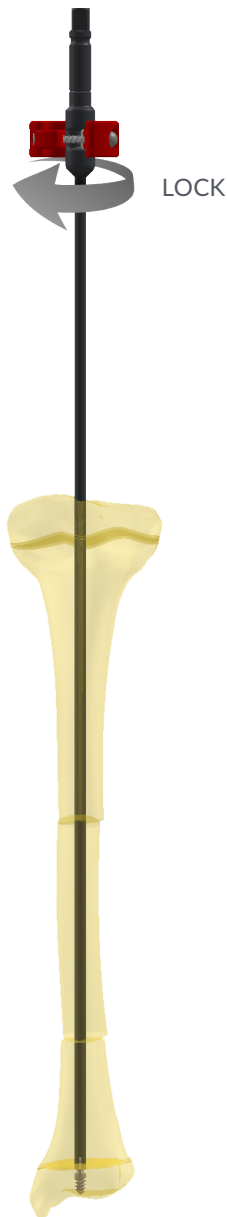Step 4: Male Driver

Insert a 2.0 mm Guide Wire retrograde from the osteotomy up through the proximal tibia. Slide the Male Driver corresponding to the Nail size over the Guide Wire up to the osteotomy.

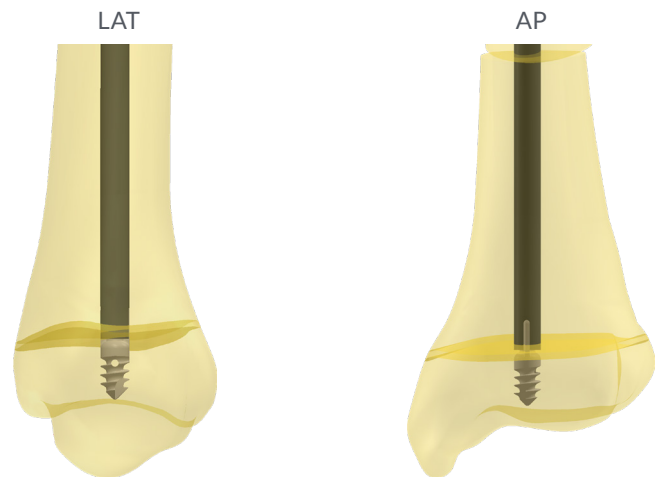
Remove the Guide Wire from the Male Driver, and insert the Male Component; ensure that the wings of the Male Component are properly engaged into the Male Driver's slots.

If uncut, the Male Drivers can be locked onto the Male Component to facilitate manoeuvring of the Nail for insertion. To lock the Male Component after it is inserted inside the Male Driver, rotate the plastic ring to the LOCK position with reference to the line on the metal shaft of the Male Driver.

Nail	Male Driver	
	Cat #	Color
Ø 3.2	MDr132-L	Yellow
4.0	MDr140-L	Red
4.8	MDr148-L	Blue
5.6	MDr156-L	Black
6.4	MDr164-L	Rust



Centered implant position in both views



Step 5: Male Component Insertion

The Male Component is advanced distally after reduction of the osteotomy (ies) and screwed into the distal epiphysis.

Verify under fluoroscope that the distal thread is positioned beyond the growth plate (otherwise normal growth may be affected.)

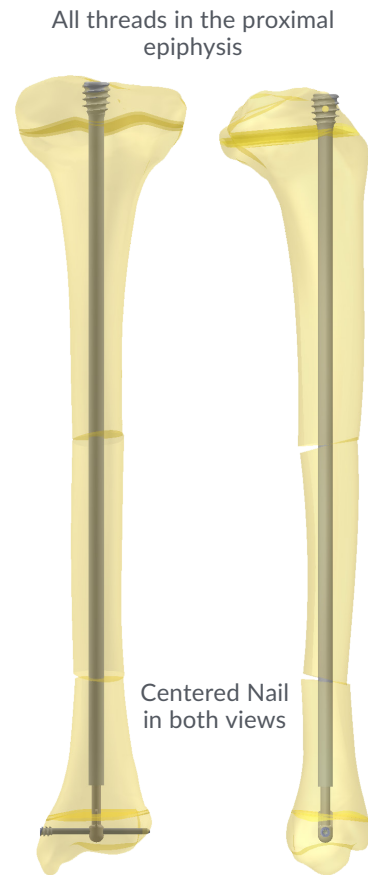
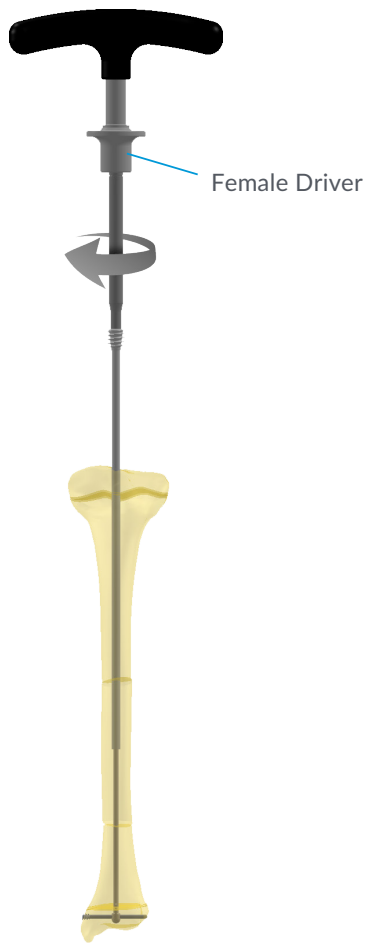
Optimal position of the Male Component in the distal epiphysis is achieved by centering the distal tip on both the A-P and the lateral views.

The fixation differs with the type of Implant chosen. Short thread and Pin fixation are available for the tibia. See 'Additional Fixation Options' (page 15) for more details on pin fixation.

Once the Male Component has been fixed into the distal epiphysis, unlock the Male by rotating the eccentric ring to the UNLOCK position before removing the Male Driver.

CAUTION: Failure to unlock the Male Driver from the Male Component may result in the implant being pulled out of the epiphysis and consequently lack of secure fixation.

CAUTION: The Male Driver is designed only to screw the Male Component. Do not use the Male Driver to reduce the fracture. Align the bone segments before advancing the driver into the canal. Incorrect use of the Male Driver could result in instrument damage.



Step 6: Male Driver Removal

(See Femur instructions Step 6)

Step 7: Female Component Cutting

(See Femur instructions Step 7)

Step 8: Female Component Insertion

Place the Female Component, previously cut to size, over the Male and screw the Female Component into the proximal tibial epiphysis using the appropriate Female Driver.

Nail	Female Driver	
Size	Cat #	Hex Size
3.2	FDR100	4.0 mm
4.0	FDR102	5.0 mm
4.8		
5.6	FDR101	
6.4		

Complete the insertion of the threaded portion of the Female in the proximal tibial epiphysis, making sure no threads are crossing the proximal growth plate. Remove the Female Driver.

CAUTION: The Female Driver should be kept aligned with the Female Component during insertion. Lateral forces (bending) may cause the failure of the hexagonal tip of the Female Driver.

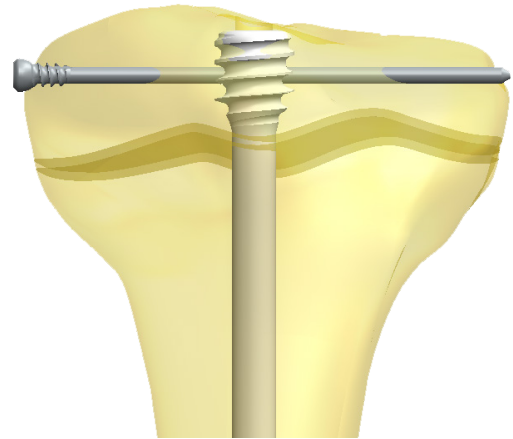
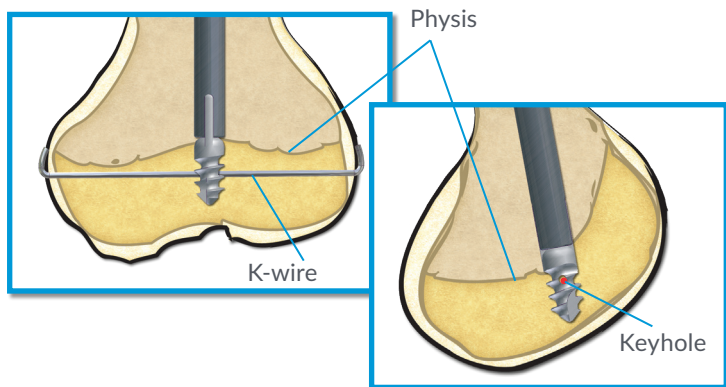
Step 9: Male Cutter

If not already pre-cut, cut the Male Component using the Male Cutter [MC200], flush with the head of the Female Component to prevent interference with the patellar tendon and articular surfaces. A full range of motion of the knee must be obtained before closing the wound. (See Femur Instructions, page 7, step 9)

Step 10: Final Result

Verify the smoothness of the cut end of the Male with the probe [PRO132-140, PRO148-156 or PRO164] of appropriate size. Finally, close the incisions.

Tibia & Humerus | Additional Fixation Options



Short Thread Inter-Locking

The short thread Male Components are designed to resist maximum pull-out forces due to growth and distraction forces. Although in most cases no extra fixation is required, a small keyhole has been added to the distal end to achieve added strength to the distal fixation. Under C-arm magnification and before the Male Driver is withdrawn, the keyhole can be visualized and a Guide Wire of appropriate size (0.7 mm for the Ø3.2 Nail, 0.9 mm for the Ø4.0 Nail and 1.1 mm for all the other Nail sizes) is introduced and locked on both cortices. To facilitate targeting of the keyhole a small drill can first be used to break the cortex and minimize deflection of the Guide Wire.

Proximal Fixation

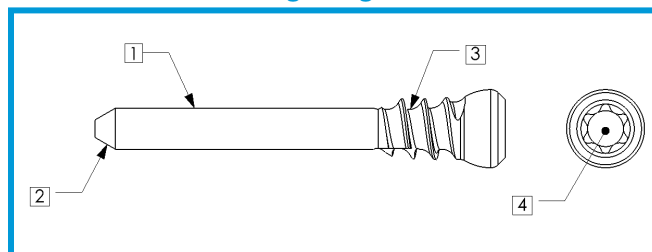
All Female Tibial/Humeral Components include a proximal hole that can accommodate a 2.0, 2.4 or 2.8 mm Guide Wire or Peg. This interlocking component should be used in poor quality bone where the threaded purchase of the Implant is not sufficient. To lock the Female component, the Male Component must be pre-cut to a level below the proximal hole prior to insertion (See step 3).



Nail Interlock		
Nail	Proximal Interlock	Distal Interlock
3.2	2.0 PEG	1.6 WIRE
4.0		1.8 WIRE
4.8		2.0 PEG
5.6	2.4 PEG	2.4 PEG
6.4	2.8 PEG	2.8 PEG

To facilitate the targeting of the LON Male Component, the image intensifier can be set to 2x magnification. Using the Male Driver, the implant can be rotated to achieve a perfect circle. Drill through the LON pin hole and the far cortex using a drill of the appropriate size. Pega Pegs and instruments are packaged in separate tray.

Pega Pegs























Pegs are available in 2.0, 2.4 and 2.8 mm diameter with lengths ranging from 16-60 mm. Pegs include the following features:


1. Smooth shaft to engage FD Component and far cortex
2. Bevel Tip to facilitate targeting
3. Threaded fixation in the proximal cortex
4. T8 Star Drive

Distal Fixation: LON and PEGs

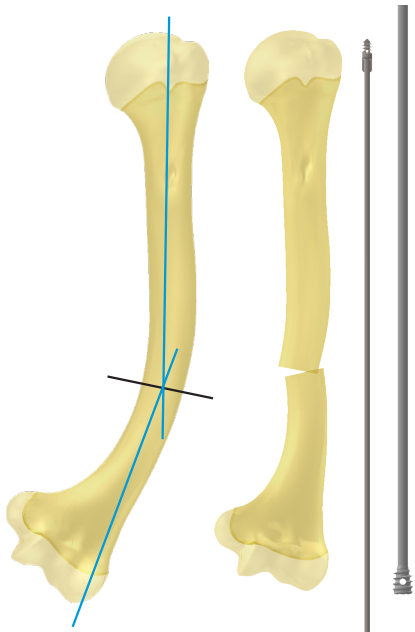
Non-threaded (LON) Male Components are used when the distal epiphysis is too small or of too poor quality for a threaded fixation. The non-threaded fixation is pushed into the epiphysis and locked with a Guide Wire or Peg of the appropriate size (see Table) which engages both cortices. Verify the final position of the distal fixation under image intensifier.

Tibia & Humerus | Implant Specifications

Catalog #	Size X Length	Proximal Fixation	Distal Fixation
Tibial and Humeral Implants Short Thread			
FD-032(SPS)-SS	Ø 3.2 X 197 Ø 3.2 X 262	 T032-SS	 M032-SS-50
FD-040(SPS)-SS	Ø 4.0 X 333	 T040-SS	 M040-SS-60
FD-048(SPS)-SS	Ø 4.8 X 404	 T048-SS	 M048-SS-70
FD-056(SPS)-SS	Ø 5.6 X 405	 T056-SS	 M056-SS-85
FD-064(SPS)-SS	Ø 6.4 X 407	 T064-SS	 M064-SS-100
Tibial and Humeral Implants Pin Locking - LON			
FDLON-T032-SS	Ø 3.2 X 194 Ø 3.2 X 259	 T032-SS	 M032-SS-LON
FDLON-T040-SS	Ø 4.0 X 330	 T040-SS	 M040-SS-LON
FDLON-T048-SS	Ø 4.8 X 400	 T048-SS	 M048-SS-LON
FDLON-T056-SS	Ø 5.6 X 401	 T056-SS	 M056-SS-LON
FDLON-T064-SS	Ø 6.4 X 401	 T064-SS	 M064-SS-LON



Humerus | Open Osteotomy Technique



Background regarding Humeral Rodding (by Dr. F. Fassier)

Traditionally, rodding of the humerus in OI has been done by two methods:

1. Antegrade through the rotator cuff
2. Retrograde (“Eiffel Tower Construct”) with two elastic nails, one inserted from the medial epicondyle and one from the lateral condyle.

In the antegrade technique, the approach is more invasive and disruptive to the soft tissue leading to longer shoulder rehabilitation. Technically, the use of a one-piece implant such as a Rush rod or SLIM Nail is relatively simple. However, insertion of the FD rod is more challenging, particularly at the moment of the insertion of the Female Component since the Male Component must be pre-cut leaving it buried in the proximal epiphysis.

In the retrograde technique, when using a static implant, the rods are likely to be too short after two years because of the proximal growth of the humerus. This leaves the proximal part of the humerus unprotected and at risk of fracture. The same risk applies with non-telescopic rods inserted from proximal to distal, but this time it is the distal humerus that is not protected and at risk of fracture.

In order to facilitate the approach and overall procedure and reduce trauma to the rotator cuff, a newer technique of telescopic retrograde rodding is described.

Diameter Consideration

Selection of the rod diameter is based on the size of the isthmus of the medullary canal.

Length considerations

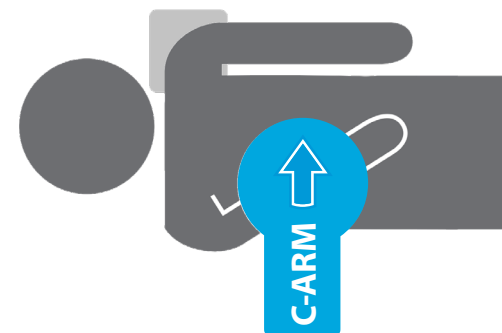
The length of both the Male and Female Components will be determined intra-op after the osteotomies have been completed.

For a retrograde approach, the choice of L (long thread) or S (short thread) is based on the height of the proximal humeral epiphysis.

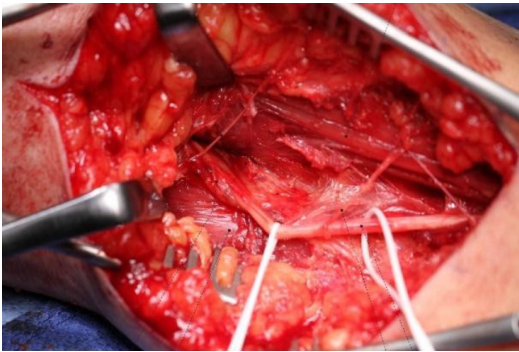
CAUTION: The retrograde approach is not advisable for a deformity occurring uniquely in the proximal third of the humerus since a distal osteotomy is required to accommodate the path of the Nail, from the lateral column to the center of the canal.

Patient Positioning

The patient is supine on a radiolucent table with the affected arm parallel to the trunk. A saline bag is placed under the shoulder. Draping must allow free access to the entire shoulder should the need of antegrade rodding becomes the only possible option. The endotracheal tube must be on the opposite side of the mouth to avoid contact during the surgery and risk of disconnection. Lastly, the C-arm is coming from the other side of the table. Note that the use of a hand table is not possible for small children.



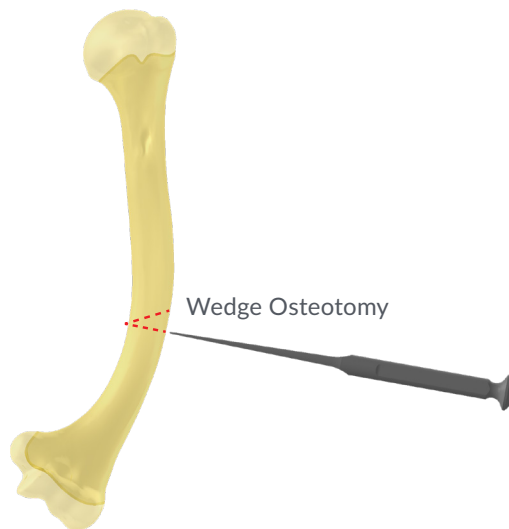
Humerus | Open Osteotomy technique



Protect radial nerve

Approach

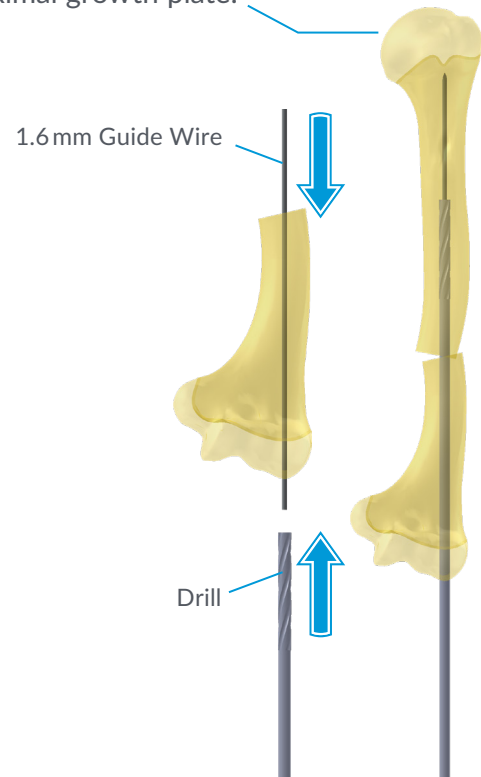
Use a classic distal lateral approach with dissection (and protection) of the radial nerve. The humerus is exposed at the level of the planned osteotomy, as verified with the C-arm. The periosteum of the humerus is cut in a semi-circular fashion, going as far as possible on the medial side of the humerus. This creates a flap of periosteum on which a 2/0 Dexon suture is attached. This flap is retracted laterally, protecting the radial nerve during the surgery.



Osteotomy

Hohman retractors are positioned around the humerus and the osteotomy is performed with an osteome after having drilled holes with a small (2.0 mm or smaller) drill bit. After completion of the osteotomy, a small wedge of bone, corresponding to the amount of correction needed to straighten the bone, is resected laterally using a rongeur.

CAUTION: Do not ream the proximal growth plate.

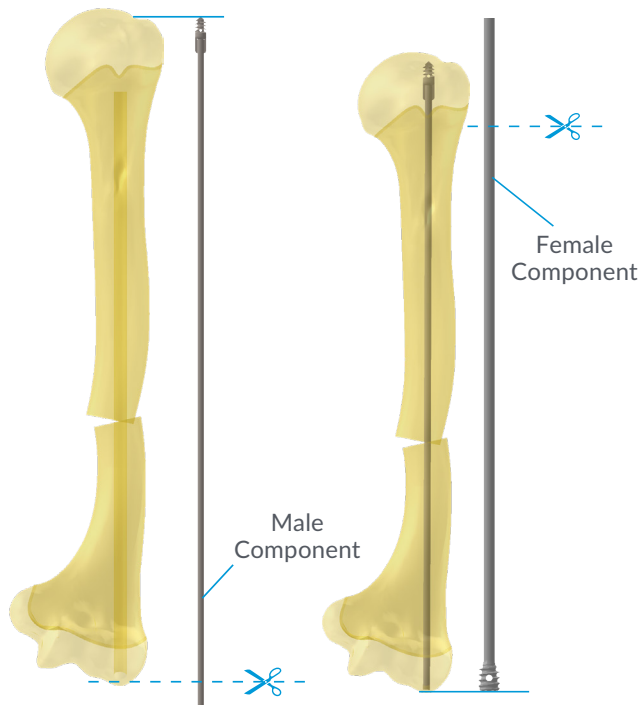


Reaming

While carefully holding the distal fragment of the humerus with a small bone clamp, use a 2.6 mm drill bit to create a canal aiming to the lateral condyle of the humerus. A 1.6 mm Guidewire is then inserted and pushed through the lateral cortex of the distal humerus, just lateral to the elbow joint. Reaming over the Guidewire with an FD Reamers is done, usually 3.2 mm for small patients, until the exit point of the canal on the lateral condyle. Reaming of the proximal humeral fragment is then performed over a Guidewire. If the proximal fragment is bowed, another osteotomy(ies) can be done percutaneously.

CAUTION: Reaming is stopped 1 cm short of the proximal humeral growth plate.

Humerus | Open Osteotomy Technique

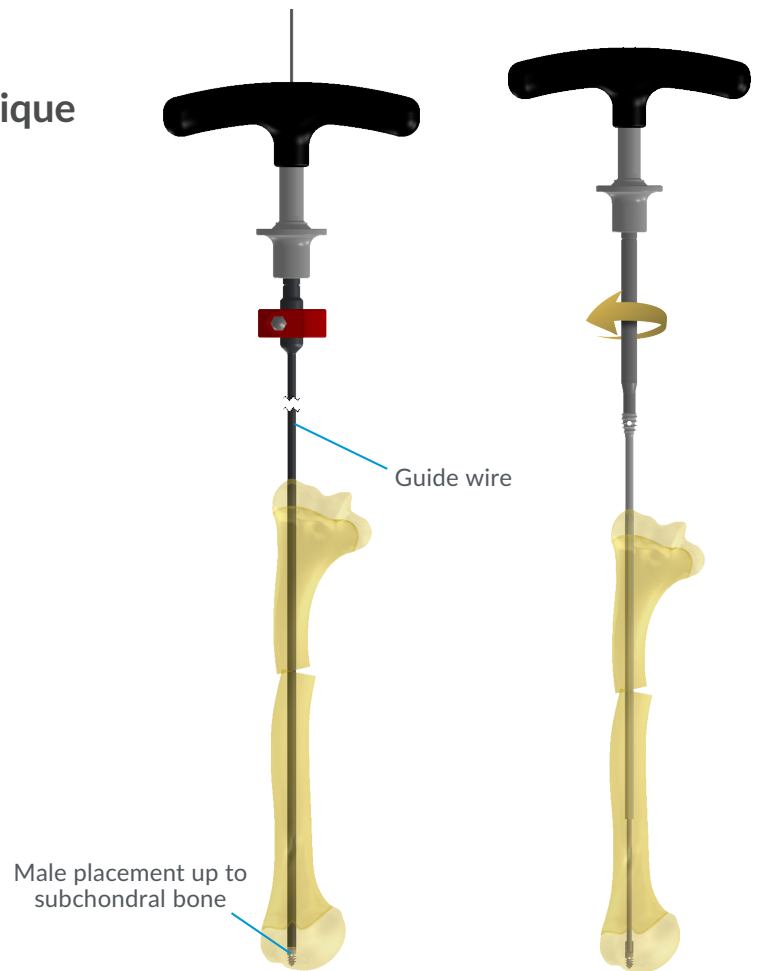


Male Component

Measure the length of the Male Component from the osteotomy up to the subchondral bone of the humeral head, and from the osteotomy down to the exit point of the reamer through the cortex of the humeral condyle. The Male Component is then cut using the Male Cutter and inserted with the Male Driver.

Advance the Male Component until all the threads are into the epiphysis. For optimal purchase, the threads should be advanced up to subchondral bone.

It is important to leave a Guidewire inside the Male Driver in order to facilitate the introduction of the Female Component. This will ease the passage of the Female in the soft tissues.

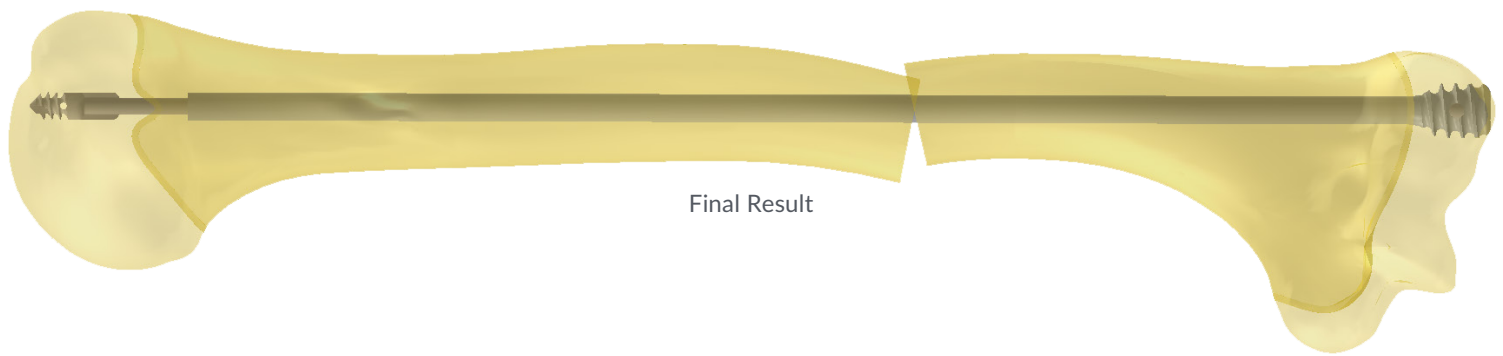


Female Component

The Female Component is cut 1 cm short of the proximal humeral physis using a high speed cutting disc (see Femur technique step 7). The Female Component is advanced over the Guide Wire which was left in the tract when the Male Driver was removed.

It should not be too difficult to feel the tip of the Male Component and push the Female over the Male. In case of difficulties, it is always possible to enlarge the entry point on the skin and position the Female Component under direct vision.

When the Female Component proximal threads are just in contact with the bone at the lateral condyle, check with C-arm that the length is appropriate: the distance between the end of the Female Component and the "wings" of the Male Component must be larger than the height of the threads. This will ensure that the Female Component will not push the Male up in the shoulder joint. Then, screw the Female Component until the threads are completely embedded in the lateral condyle.



Final Result

Closure and Post-op Care

The periosteal flap of the humerus is sutured to the soft tissue (muscle) on the opposite side of the bone, preventing the radial nerve to get adherent to the callus which will form.

Post-operative immobilization is provided with a custom-made Vietnam sling for youngsters and a Stevenson brace for older patients. Usually, 3 weeks immobilization is sufficient to achieve rotational stability and then begin rehab.

Due to the fact that the shoulder joint is not affected with this technique, the shoulder ROM is easily regained. With regards to the elbow ROM, be sure that the distal humeral osteotomy/fracture is completely healed before allowing full extension of the elbow. Any attempt to extend the elbow creates an extension stress at the osteotomy/fracture site and may lead to a non-union, a complication very difficult to treat.

Remarks

This technique is much easier than antegrade IM nailing of the humerus through the rotator cuff. However, it leaves a mild varus deformity of the distal humerus. The normal anatomical axis ends in the olecranon fossa, but with this technique, the anatomical axis ends in the lateral column of the distal humerus.

CAUTION: Federal law restricts this device to sale by or the order of a Physician.

CAUTION: Devices are supplied Non-Sterile. Clean and sterilize before use according to instructions.

CAUTION: Implants components are single-use. Do not reuse.

CAUTION: Only those instruments and implants contained within this system are recommended for use with this technique. Other instruments or implants used in combination or in place of those contained within this system is not recommended.

NOTE: This technique has been provided by one of our medical advisors only as guidance and it is not intended to limit the methods used by trained and experienced surgeons.

OrthoPediatics, ArmorLink, BandLoc Duo, Drive Rail, PediFlex, PediFoot, PediFrag, PediGraft, PediLoc, PediNail, PediPlates, PLEO, QuickPack, RESPONSE, Scwire, ShieldLoc, TorqLoc, PediPedal and the OP and Pedi logos are trademarks of OrthoPediatics Corp. ApiFix and Orthex are trademarks of wholly-owned subsidiaries of OrthoPediatics Corp.

OrthoPediatics is a registered trademark in Brazil, S.Korea, and the U.S.A. PediLoc and PediPlates are registered trademarks in Chile and the U.S.A. The OP logo is a registered trademark in Colombia, European Union, Japan, and the U.S.A. The Pedi logo is a registered trademark in Argentina, Australia, Brazil, Chile, Colombia, European Union, Israel, Mexico, New Zealand, S.Korea, Taiwan, Turkey, and the U.S.A. ApiFix is a registered trademark in the U.S.A. ArmorLink is a registered trademark in the U.S.A. Scwire is a registered trademark in the U.S.A. ShieldLoc is a registered trademark in the U.S.A. TorqLoc is a registered trademark in the U.S.A. BandLoc Duo is a registered trademark in the U.S.A. Orthex is a registered trademark in the U.S.A. QuickPack is a registered trademark in the U.S.A. OrthoPediatics is an exclusive licensee of the DF2 trademark.



1111 Aut. Chomedey, Laval, QC CANADA, H7W 5J8
ph: 450-688-5144 | fax: 450-233-6358
www.orthopediatrics.com
© 2024 OrthoPediatics Canada, Inc.

CE 0413

© 2024 OrthoPediatics Canada - FD-ST-EN Rev M (Jan. 2024).